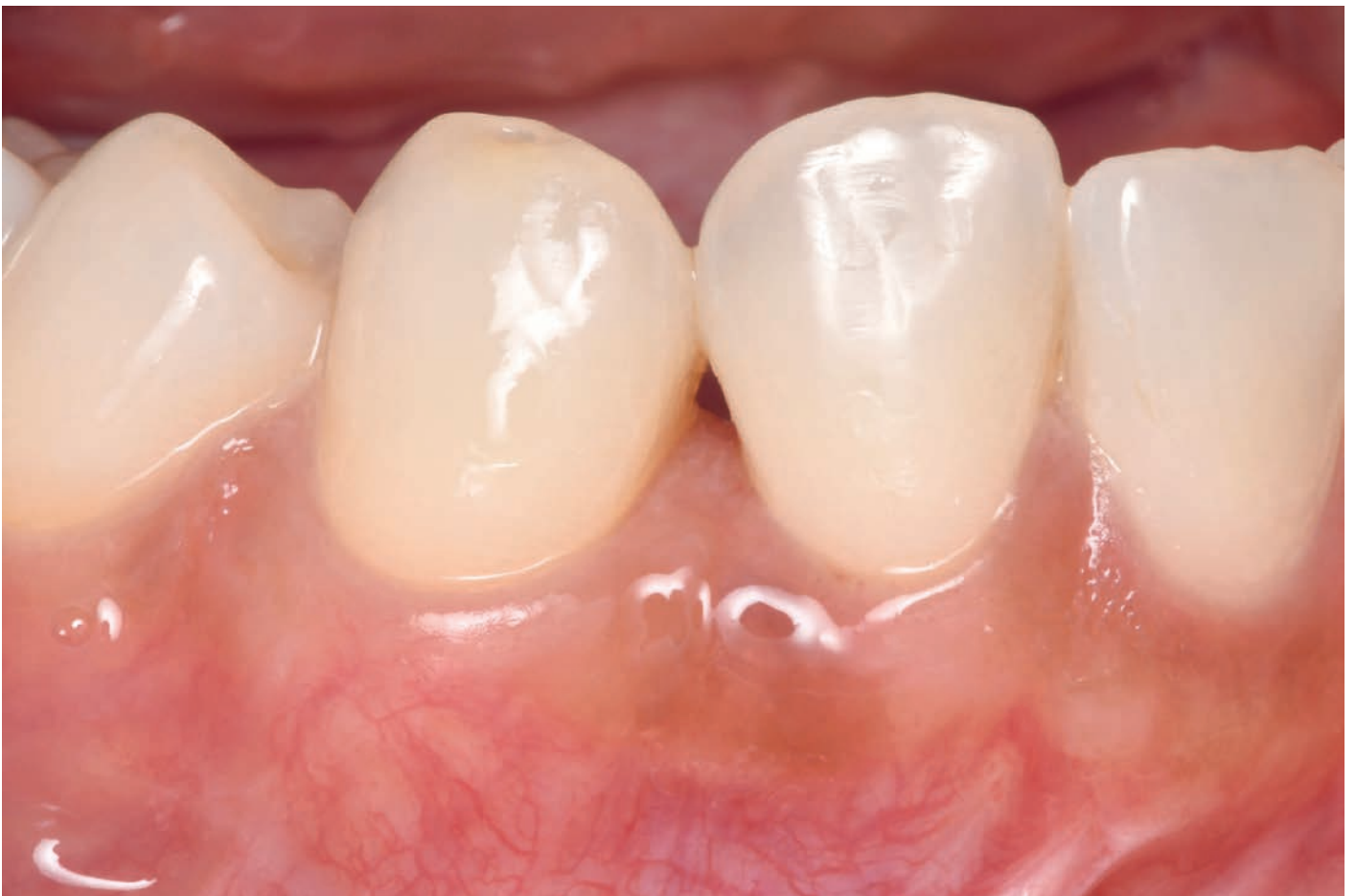
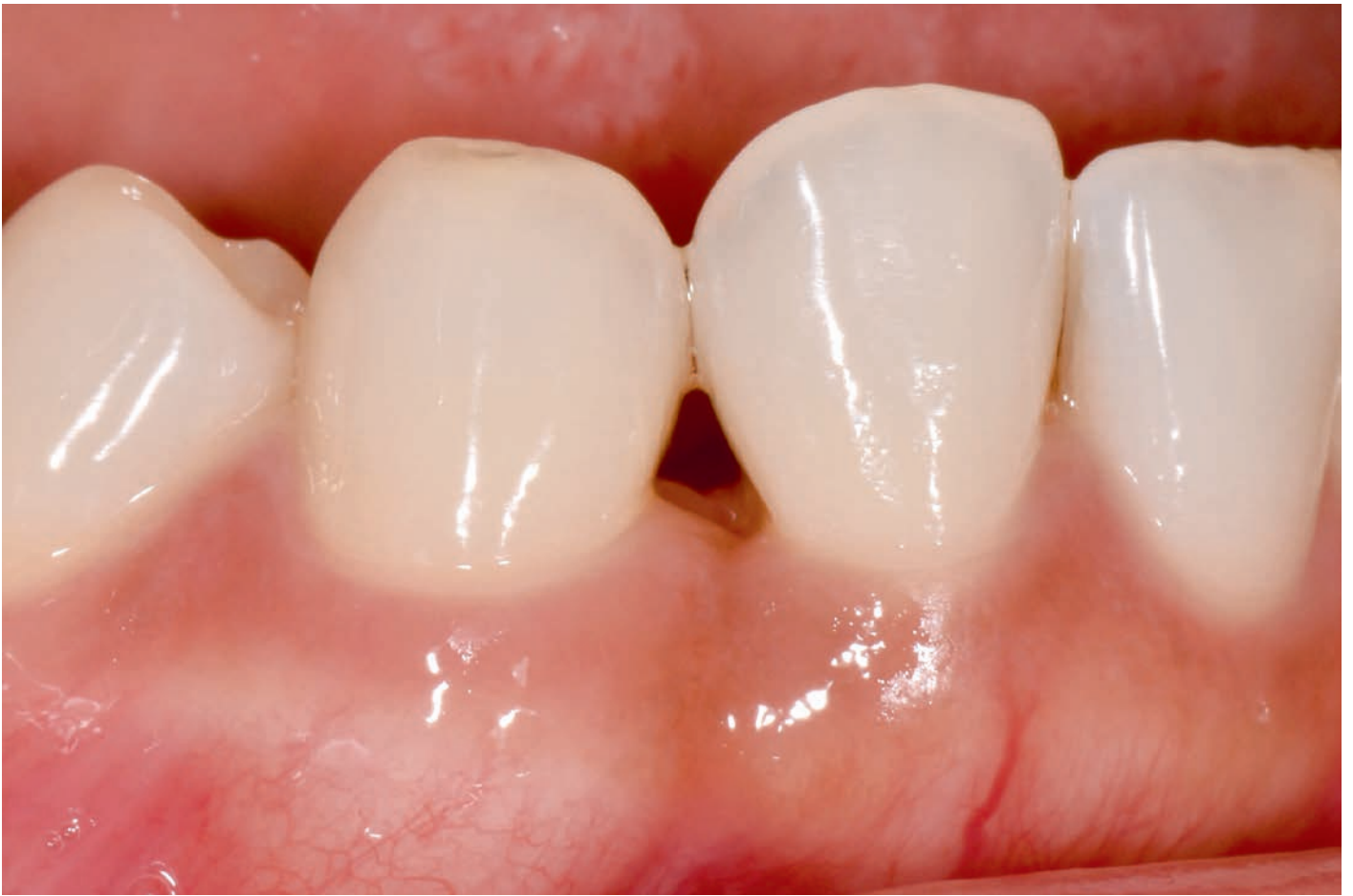


Shota Tsuji, DDS, MS
Shu Hoshi, DDS, PhD
Shogo Maekawa, DDS, PhD

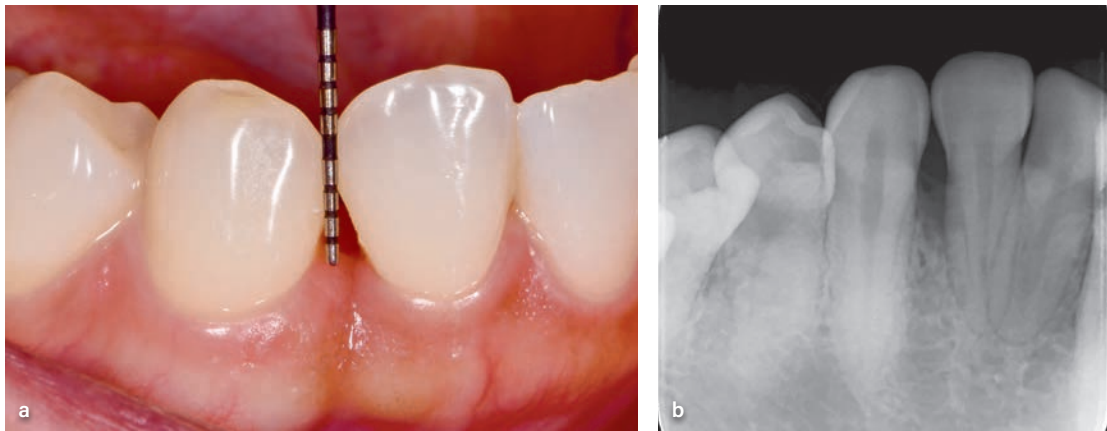
Papillary Coronal Anchorage Technique for Periodontal Reconstruction of the Infrabony Defect and Interdental Papilla: A Case Report

Esthetic issues and phonetic disturbances frequently occur after periodontal regeneration of the anterior teeth, even if treatment is supposed to be successful. Conventional regenerative techniques predominantly target infrabony defects and often inadequately address the loss of the interdental papilla. This study introduces the papillary coronal anchorage technique, a novel modified tunnel surgical procedure, to facilitate reconstruction of the interdental papilla. This method allows for coronal movement of the entire interdental papilla, without incisions at the papilla, to facilitate primary wound healing. Using a combination of bone grafts and recombinant human fibroblast growth factor-2 and coronally anchoring the tunnel-like flap using sutures, reconstruction of both the infrabony defect and the interdental papilla were achieved. The papillary coronal anchorage technique is effective, as it enables the simultaneous reconstruction of both the infrabony defect and the interdental papilla. *Int J Periodontics Restorative Dent* 2026;46:43–51. doi: 10.11607/prd.7005

Keywords: dental papilla, fibroblast growth factor-2, periodontal surgery, periodontitis, periodontium, regeneration

Infrabony defects in the esthetic zone require attachment gain through periodontal regenerative therapy and simultaneous reconstruction of the interproximal soft tissues. Periodontal regeneration therapy has been beneficial for infrabony defects, yet it does not consistently lead to attachment levels comparable to those of a healthy periodontium.¹ Consequently, soft tissue defects in the interdental papilla (black triangles) often occur after periodontal regeneration, but treatment for these tissue defects has not yet been established.

Several approaches have been proposed to address these tissue deficiencies.^{2–7} However, they are predominantly soft-tissue approaches, such as subepithelial connective tissue grafting, as they were designed to address papilla deficiency in the healthy or diseased periodontium. Nordland and Tarnow reported improvement in the interdental papillary tissue after a subepithelial connective tissue graft (SCTG) using a microsurgical technique, representing the augmentation of the interdental papilla.⁸



▲ **Fig 1** (a and b) Clinical and radiographic views, respectively, at the initial visit.

Rasperini et al⁹ recently introduced the coronally advanced entire papilla preservation flap, which combines the concepts of periodontal regenerative therapy and SCTG to improve the attachment levels in the interdental papilla. This approach has established a method for reconstruction in the interdental area that considers both soft and hard tissues.⁹

This clinical case report aimed to describe the papillary coronal anchorage technique (P-CAT) designed for interproximal attachment gain in the esthetic zone. When used to treat both the infrabony defect and the recessed interdental papilla, this technique involves minimally invasive interdental papillary incisions and the application of biologic materials and bone grafts to achieve interproximal reconstruction in the interdental papilla affected by periodontitis.

Case Presentation

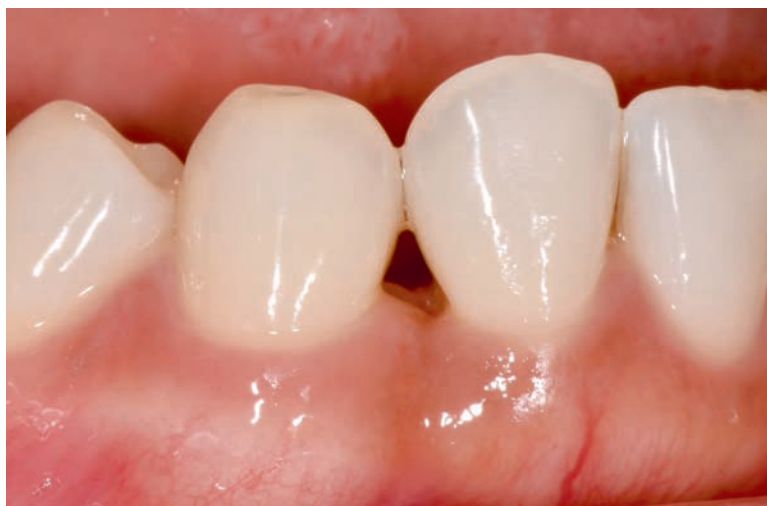The patient was a 34-year-old woman with no history of systemic diseases or smoking. Clinical examination revealed a probing pocket depth (PPD) of 7 mm with bleeding on probing (BOP) and a 10-mm clinical attachment level (CAL) on the distal aspect of the mandibular right lateral incisor. No tooth was mobile. Radiographic examination revealed a vertical bone defect distal to the mandibular right lateral incisor (Fig 1). Periodontitis stage III or grade C was diagnosed. The

patient sought resolution of the periodontitis and the esthetic issues resulting from the interdental papilla loss. Conventional periodontal treatment can cause interproximal gingival recession, potentially leading to additional esthetic problems. Therefore, periodontal regenerative therapy was performed to regenerate the tissue in the infrabony defect of the interdental area and to reconstruct the interdental papilla. The interdental papilla between the lateral incisor and canine had a soft tissue height reduction of 3 mm, which was classified as Class 2 according to Nordland's papilla classification.⁸ Bone loss from the interdental papilla was observed on both the buccal and lingual aspects. Therefore, 3D tissue reconstruction was necessary to reconstruct both the infrabony defect and the interdental papilla to meet patient demands.

Case Management

After the initial examination, the patient was provided oral hygiene instructions. Nonsurgical periodontal treatment was performed under local anesthesia in a single session. After nonsurgical intervention, 500 mg amoxicillin and 250 mg metronidazole were prescribed for 7 days. At the 4-week posttreatment reevaluation, the 6-mm PPD and 9-mm CAL persisted, although the BOP had resolved (Fig 2). There was a minimal reduction (approximately 3 mm) in the interdental papilla height compared to that recorded at the first visit. Therefore, periodontal regenerative

► **Fig 2** Buccal view at reevaluation prior to regenerative surgery.



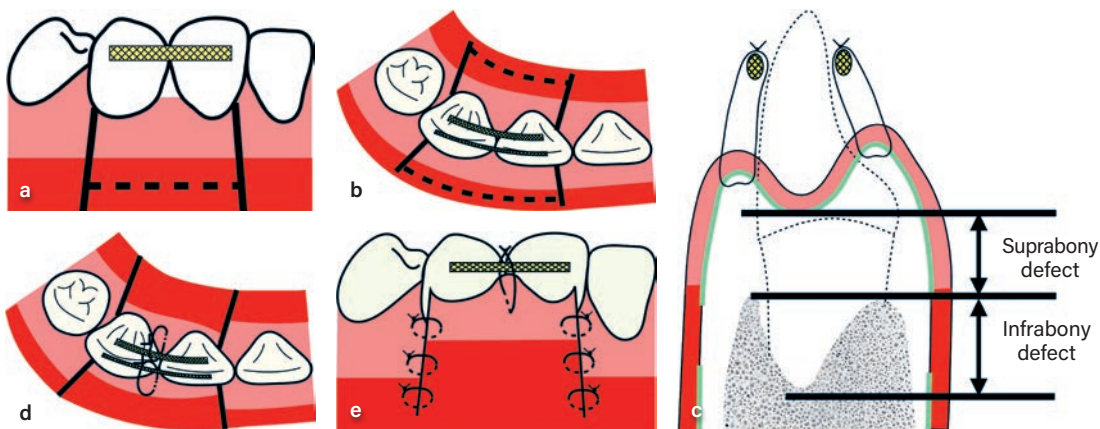
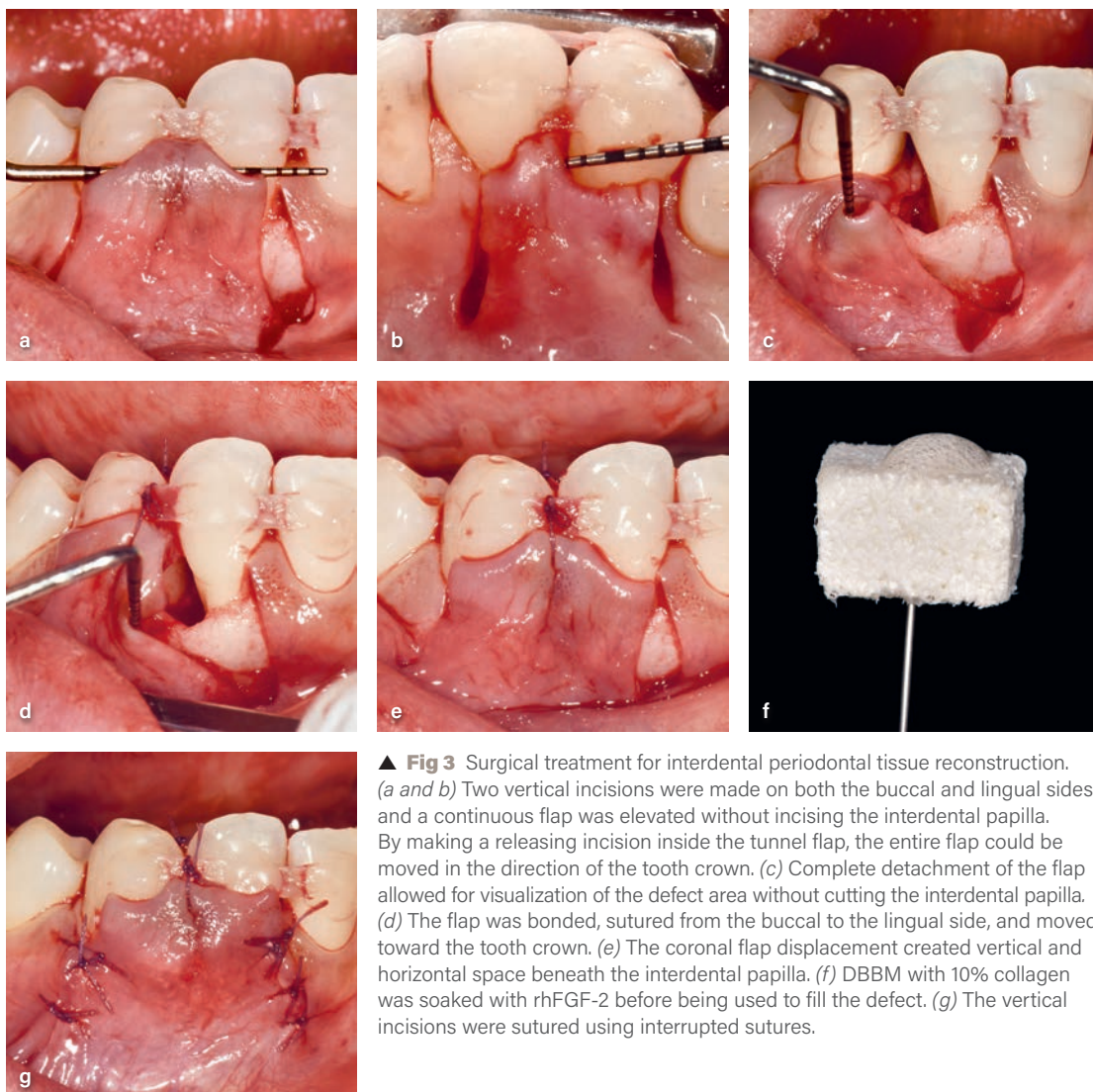
surgery was planned to improve the condition of the periodontal tissue and reconstruct the interdental papillae.

Prior to surgery, fiber-reinforced resin was bonded to both the buccal and lingual sides of the lateral incisor and canine. Local anesthesia with 2% lidocaine and 1:80,000 epinephrin was administered. Vertical incisions were made in four areas: mesial to the lateral incisor, distal to the canine, and on both the buccal and lingual aspects, extending beyond the mucogingival junction. After creating the vertical incisions, intrasulcular incisions were made around the affected teeth. A full-thickness flap was created on the buccal and lingual sides without incising the interdental papilla. These incision and flap-elevation techniques provided a clear view of the bone defect between the lateral incisor and canine, allowing for the removal of granulation tissue and root planing, similar to the conventional flap design. To enable the coronal shifting of the buccal and lingual interdental papillary tunnel flaps, horizontal incisions were made from the inner side of the mucosal area of each buccal and lingual tunnel to create releasing incisions, and the buccal and lingual flaps were moved in the coronal direction (Figs 3a to 3c). Granulation tissue in the defect area was excised, followed by scaling and root planing. A 3-wall vertical bone defect with a depth of 3 mm was identified distal to the lateral incisor.

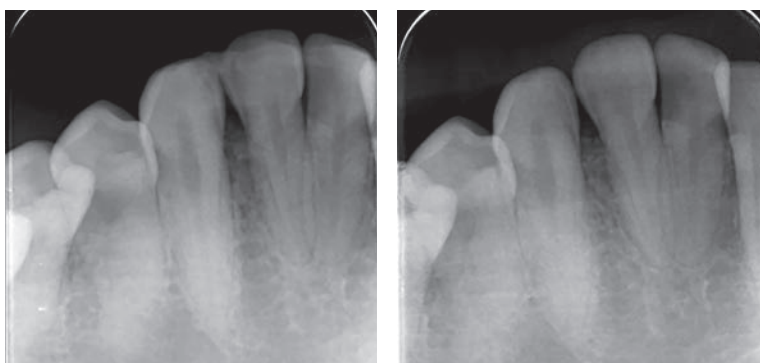
A tunnel flap was prepared for both the buccal and lingual sides in the coronal direction, and

fiber-reinforced resin was used as an anchor. Sling sutures were placed on both the buccal and lingual sides, as well as in the coronal direction (Fig 3d). By laterally shifting the buccal flap, it was confirmed that biomaterials could be directly visualized and inserted into the defect (Fig 3e). Recombinant human fibroblast growth factor-2 (rhFGF-2; Regroth, Kaken) was applied to the root surfaces of both the infrabony and suprabony defects. Following the protocols established in previous rhFGF-2 clinical studies, the root surface was not treated. After rhFGF-2 application, deproteinized bovine bone mineral (DBBM) with 10% collagen (Bio-Oss Collagen, Geistlich), which had been pretrimmed to the defect size and soaked in rhFGF-2 (Fig 3f), was grafted from the buccal side. The vertical incisions were closed using interrupted sutures (Fig 3g). The incision and suturing methods are shown in Fig 4.

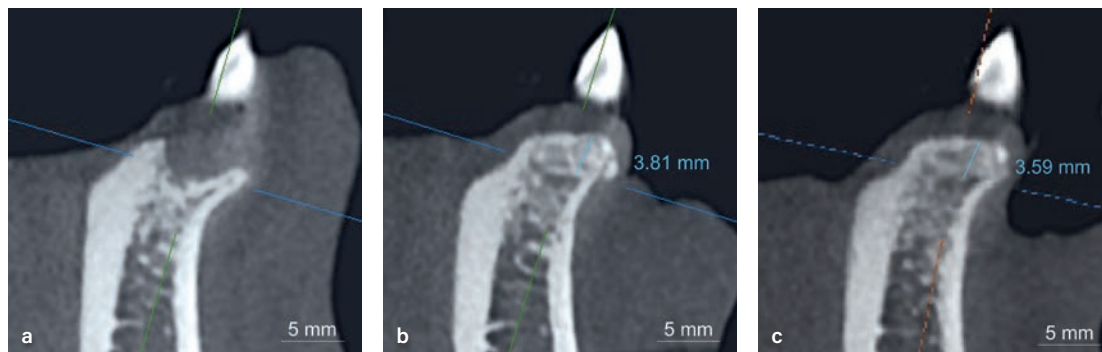
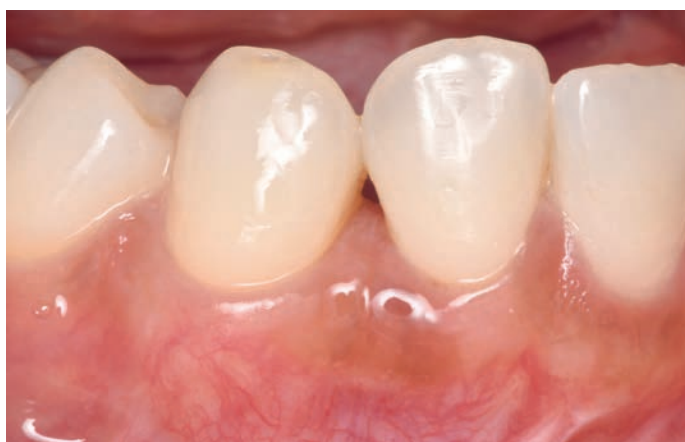The patient was advised to not brush for 4 weeks and avoid excessive pressure or mechanical stimulation in the surgical area. The prescribed medications included 60 mg loxoprofen sodium hydrate as needed; 500 mg of amoxicillin every 8 hours for 7 days; and a mouthrinse containing 0.12% chlorhexidine gluconate every 12 hours. The patient was scheduled for follow-ups at 1, 2, 4, and 8 weeks. Suture removal was performed at 4 weeks. Subsequently, the patient was instructed to visit the clinic every 2 months until reevaluation at 10 months. During this period, the patient was enrolled in a strict plaque-control program.



► **Fig 5** (a and b) Intraoral radiographs taken postsurgically and at the 23-month follow-up, respectively.



► **Fig 6** Clinical view at 23 months.



▲ **Fig 7** (a to c) Buccolingual cross-sectional CBCT images before surgery and 14 and 23 months after surgery, respectively. (a) A shallow vertical bone defect was observed. (b) The bone defect is filled, and radiographic bone fill can also be observed in the coronal direction. (c) The radiographic bone fill exhibited minimal change at 23 months postoperative.

Clinical Outcomes

No postsurgical complications were observed in the interdental papillary soft tissue, leading to a highly favorable outcome. Immediately after the procedure, slight swelling and pain persisted for 3 days, but the subsequent recovery was smooth and favorable. At the time of reevaluation, a PPD of 3 mm, a CAL of 4 mm, and radiographic bone fill were observed in the interdental space between the lateral incisor and canine on a periapical

radiograph (Fig 5). As the time of writing, the patient has been followed up for 23 months (Fig 6), and the clinical and radiographic findings of the surgical site are excellent so far. The interdental area is filled with soft tissue, which is satisfactory. Comparison of the pre- and posttreatment CBCTs revealed radiographic bone fill in both the infrabony and suprabony defects (Fig 7). Measurements on the computer planning software (LAND marker, iCat Corporation) revealed a radiographic

bone fill of 3.81 mm coronally from the area considered to be the defect's base.

Discussion

Interdental papillary deficiencies in the esthetic zone can lead to esthetic and phonetic challenges. However, interventions such as adjacent tooth preparation, root canal treatment, and orthodontic extrusion may be required to address them.^{10,11} These approaches, aimed at achieving esthetic results, often damage the adjacent tooth structure. Consequently, methods of interdental papilla reconstruction have been proposed; however, a gold standard treatment has not yet been established.¹

One reason why the reconstruction of the interdental papilla is challenging may be the limited blood supply to this area. Limited blood supply to the interdental papilla is a challenge that has already been faced in the flap management of periodontal regenerative therapy. In periodontal regenerative treatment, primary closure of the interdental papilla can be achieved by determining the incision method and the area of the interdental papilla. Primary closure is crucial because it affects the results of regenerative treatment. Despite these considerations, the incision is believed to inhibit the blood supply to the interdental papilla. Consequently, the probability of primary closure after surgical treatment is not high.¹² In response to this challenge, less-invasive incision techniques have been proposed that do not make an incision that obstructs blood supply in the interdental papilla.^{13–15} These techniques involve making a minimal incision at a site distant from the infrabony defect, moving the flap laterally or coronally, and ensuring visibility to the defect area while maintaining the blood supply of the interdental papilla to achieve better clinical results. Aslan et al¹⁶ reported good outcomes with the entire papillary preservation technique for periodontal regenerative therapy. By avoiding incisions in the interdental papilla, they achieved a 100% primary closure rate.¹⁶ Thus, it is considered highly important to perform regenerative treatment of the interdental area without making an incision in the

interdental papilla, as this can facilitate primary closure in the interdental area and ultimately lead to better clinical outcomes.¹⁷

Periodontal regeneration, which avoids direct incisions on the interdental papilla, is highly advantageous in terms of blood supply, but it complicates defect visibility. Several approaches have been proposed to preserve the visibility of the defect without making incisions in the interdental papilla. These can be broadly classified into two categories: making a horizontal incision on the apical side of the defect to gain visibility^{6,18} and making a vertical incision at a position distant from the defect.^{9,13} The horizontal incision allows for an increase in the mesiodistal width of the flap, thus facilitating the coronal movement of the entire flap, including the interdental papilla. However, because the blood supply to the gingiva on the buccal and lingual sides originates from the alveolar mucosa below the gingiva, horizontal incisions are more likely to impair the blood flow to the interdental papilla than vertical incisions.¹⁹ For cases where visibility is gained through a vertical incision, it is quite challenging to move the entire interdental papilla coronally because there is only one incision. Nonetheless, vertical incisions may offer advantages over horizontal incisions when the maintenance of the blood supply to the interdental papilla is prioritized. Considering that the interdental papilla is a tissue with a limited blood supply, P-CAT, which uses only vertical incisions and avoids horizontal incisions, is advantageous for blood supply and allows significant coronal movement of the entire interdental papilla. This makes it promising for papilla reconstruction.

Periodontal regeneration using rhFGF-2 has emerged as one of the beneficial treatment modalities.²⁰ A multicenter, randomized, blinded, active-controlled study demonstrated that the linear alveolar bone growth for patients with 6-mm PPD and ≥ 4 -mm infrabony defects was 1.93 mm for the rhFGF-2 group and 1.36 mm for the enamel matrix derivative (EMD) group. The study also found that the clinical outcomes after using rhFGF-2 were not inferior to those after using EMD. While rhFGF-2 alone leads to successful outcomes in periodontal regenerative therapy, the use of bone fillers may be needed for

noncontained defects.²¹ During a 4-year follow-up of a randomized controlled clinical trial comparing periodontal regenerative therapy with FGF-2 alone and FGF-2 combined with DBBM, radiographic bone fill was significantly more enhanced with combination therapy than with FGF-2 alone. Combination therapy may be more effective than the solo use of FGF-2 in 1- and 2-wall defects.²² The combination of FGF-2 and DBBM has been also found to improve clinical outcomes, as well as cell proliferation, angiogenesis, and osteogenic differentiation.²³ Additionally, Shirakata et al compared regenerative treatments using FGF-2 and various bone grafts for a 1-wall defect in an animal study.²⁴ Histologic results showed that the combination of FGF-2 and DBBM led to a significantly greater new bone area than FGF-2 alone or in combination with beta-tricalcium phosphate or carbonate apatite (CO₃Ap). Therefore, regenerative therapy utilizing a combination of FGF-2 and DBBM may be an optimal combination therapy currently available.

Furthermore, periodontal regenerative therapy has recently been adopted for infrabony and suprabony defects characterized by horizontal bone loss or shallow vertical bone defects. Di Tullio et al²⁵ applied EMD to suprabony defects with PPDs ≥ 5 mm using a simplified papilla preservation flap. The CAL gain was 2.80 ± 0.86 mm when EMD was used, compared to 1.04 ± 0.61 mm when EMD was not used. This indicates that periodontal regenerative therapy can provide consistent results even for suprabony defects.²⁵ In other studies, treating suprabony defects with open flap debridement (OFD) led to a mean attachment gain of 0.97 ± 0.92 mm, whereas the combination of OFD with EMD led to a significantly different gain of 1.55 ± 0.90 mm. In sites where the initial PPD was ≥ 7 mm, the use of EMD resulted in an average attachment gain of 2.72 ± 1.80 mm, while using OFD alone yielded gains of 0.78 ± 0.62 mm.²⁶ Based on these findings, consistent results have been achieved with periodontal regenerative therapy for suprabony defects. Furthermore, there has been a report of better clinical outcomes with regenerative therapy than with OFD for horizontal bone loss.²⁷ These findings suggest that regenerative

therapy may be applicable to both infrabony and suprabony defects.

Several methods have been proposed for the reconstructive treatment of infrabony and suprabony defects, including the interdental papilla. Mourlaas et al employed the entire papillary preservation technique to minimize surgical intervention for the interdental papilla and used EMD and demineralized freeze-dried bone allograft for periodontal tissue regeneration therapy.²⁸ By also incorporating SCTG, they achieved favorable outcomes for recession type 3 (RT3) cases.²⁸ Additionally, Ogawa et al demonstrated the potential for reconstruction of supra-alveolar periodontal tissue, including the interdental area, by making incisions at sites away from the interdental papilla using the nonincised papillae surgical approach, along with SCTG, CO₃Ap, and rhFGF-2.²⁹

These approaches avoid incisions in the interdental papilla, maintain blood supply, and combine periodontal regenerative therapy with SCTG. Regenerative therapy was applied to the infrabony defects, whereas connective tissue was used to treat suprabony defects to reconstruct the periodontal tissues. These methods are considered effective because they allow simultaneous root coverage and gingival phenotype modification in patients with infrabony defects. In contrast, P-CAT represents a hard tissue reconstructive approach for suprabony defects, which differs from these methods.

In sites with a history of periodontitis, papillary deficiency requires not only an increase in the soft tissue volume of the interdental papilla, but also regeneration of the alveolar bone, periodontal ligament, and cementum. In P-CAT, a minimally invasive incision is made in the interdental papilla, and space is secured not only through bone grafting, but also by making a releasing incision in the papilla flap with bonding sutures. This allows the interdental papillary tissue to advance coronally beyond its presurgical height. By utilizing biologic materials, this method might induce the regeneration of periodontal tissue in the interdental papilla to achieve interproximal attachment gain. A distinctive feature was that no incisions are made on the interdental papillae. Instead, releasing incisions are made on the buccal and lingual sides, thus

preserving the height and blood supply of the interdental papillary tissue. Traditionally, periodontal regenerative treatment has been focused on tissue regeneration in infrabony defects. However, the CBCT images in the present case revealed radiographic bone fill of the infrabony defect that also extended coronally. This suggests that using the P-CAT technique facilitates radiographic bone fill in both the infrabony defect and achieves positive bone architecture, as detected by 3D and 2D imaging. By obtaining clinically stable positive bone architecture in the interdental area, the soft tissues automatically move toward the coronal position, leading to the reconstruction of the interdental papilla. This approach may lead to better long-term stability of the interdental papilla than traditional reconstruction using SCTG to increase the soft tissue volume. By focusing on the underlying alveolar bone reconstruction, a more predictable and comprehensive approach to interdental papillary reconstruction can be achieved.

It is essential to emphasize that the application of this technique cannot be justified solely by the absence of the infrabony defect. Favorable clinical outcomes can be achieved by adapting treatment to both the intrabony defect and the interdental papilla. In addition to P-CAT, the mesiodistal distance of the interdental space, gingival phenotype, and use of rhFGF-2 and nonresorbable bone grafts contributed to positive clinical outcomes and CBCT findings.

Healing after periodontal regenerative therapy for the suprabony area has not been confirmed by histologic analysis, and further investigation is required. Future studies should explore the long-term stability of the interdental papilla after using P-CAT to determine whether these levels can be maintained.

Conclusions

P-CAT may be a technique that simultaneously addresses the improvement of periodontal defects and reconstruction of interdental papillae for interproximal attachment loss in an esthetic area. One significant advantage is that it avoids incisions in the interdental papilla, which ensures a predictable

outcome of periodontal regenerative treatment. Using a fiber-reinforced resin as an anchor, P-CAT facilitates the movement and stabilization of the entire interdental papillary tissue coronally. This approach not only addresses infrabony defects but also provides reconstruction of the interdental papilla tissue.

Acknowledgments

The authors declare no conflicts of interest.

References

1. Rasperini G, Tavelli L, Barootchi S, et al. Interproximal attachment gain: The challenge of periodontal regeneration. *J Periodontol* 2021;92:931–946.
2. Azzi R, Etienne D, Carranza F. Surgical reconstruction of the interdental papilla. *Int J Periodontics Restorative Dent* 1998;18:466–473.
3. Nemcovsky CE. Interproximal papilla augmentation procedure: A novel surgical approach and clinical evaluation of 10 consecutive procedures. *Int J Periodontics Restorative Dent* 2001;21:553–559.
4. Feuillet D, Keller JF, Agossa K. Interproximal tunneling with a customized connective tissue graft: A microsurgical technique for interdental papilla reconstruction. *Int J Periodontics Restorative Dent* 2018;38:833–839.
5. Sharma E, Sharma A, Singh K. The role of subepithelial connective tissue graft for reconstruction of interdental papilla: Clinical study. *Singapore Dent J* 2017;38:27–38.
6. Kashani H, Vora MV, Kuraji R, Brody H, Kapila YL. Rebuilding the interproximal papilla: Description of “tube” technique and two case reports. *Clin Adv Periodontics* 2021;11:17–21.
7. Kazarian E, Inozemtseva K, Lebedeva E. A novel 3D tunneling surgical technique (3DT) for the treatment of gingival recessions with reconstruction of the deficient interdental papilla and interproximal attachment regeneration: Case series. *Int J Periodontics Restorative Dent* 2025;45:31–45.
8. Nordland WP, Tarnow DP. A classification system for loss of papillary height. *J Periodontol* 1998;69:1124–1126.
9. Rasperini G, Kazarian E, Aslan S. Coronally advanced entire papilla preservation (CA-EPP) flap in the treatment of an isolated intrabony defect to promote buccal and interproximal soft tissue stability: Case reports. *Int J Periodontics Restorative Dent* 2024;44:9–16.
10. Prato GP, Rotundo R, Cortellini P, Tinti C, Azzi R. Interdental papilla management: A review and classification of the therapeutic approaches. *Int J Periodontics Restorative Dent* 2004;24:246–255.
11. Cardaropoli D, Re S. Interdental papilla augmentation procedure following orthodontic treatment in a periodontal patient. *J Periodontol* 2005;76:655–661.
12. Cortellini P, Tonetti MS, Lang NP, et al. The simplified papilla preservation flap in the regenerative treatment of deep intrabony defects: Clinical outcomes and postoperative morbidity. *J Periodontol* 2001;72:1702–1712.

13. Aslan S, Buduneli N, Cortellini P. Entire papilla preservation technique: A novel surgical approach for regenerative treatment of deep and wide intrabony defects. *Int J Periodontics Restorative Dent* 2017;37:227–233.
14. Moreno Rodríguez JA, Ortiz Ruiz AJ, Caffesse RG. Periodontal reconstructive surgery of deep intraosseous defects using an apical approach. Non-incised papillae surgical approach (NIPSA): A retrospective cohort study. *J Periodontol*. 2019;90:454–464.
15. Najafi B, Kheirieh P, Torabi A, Cappetta EG. Periodontal regenerative treatment of intrabony defects in the esthetic zone using modified vestibular incision subperiosteal tunnel access (M-VISTA). *Int J Periodontics Restorative Dent* 2018;38(suppl):e9–e16.
16. Aslan S, Buduneli N, Cortellini P. Clinical outcomes of the entire papilla preservation technique with and without biomaterials in the treatment of isolated intrabony defects: A randomized controlled clinical trial. *J Clin Periodontol* 2020;47:470–478.
17. Pei X. New surgery approaches preserving entire papilla to treat isolated interdental intrabony defects: A narrative review. *Clin Exp Dent Res* 2021;7:719–725.
18. Calzavara D, Morante S, Sanz J, et al. The apically incised coronally advanced surgical technique (AICAST) for periodontal regeneration in isolated defects: A case series. *Quintessence Int*. 2021 Dec 1;53(1):24–34.
19. Mörmann W, Ciancio SG. Blood supply of human gingiva following periodontal surgery. A fluorescein angiographic study. *J Periodontol* 1977;48:681–692.
20. Kitamura M, Akamatsu M, Kawanami M, et al. Randomized Placebo-controlled and controlled non-inferiority phase III trials comparing trafermin, a recombinant human fibroblast growth factor 2, and enamel matrix derivative in periodontal regeneration in intrabony defects. *J Bone Miner Res* 2016;31:806–814.
21. Cortellini P, Tonetti MS. Focus on intrabony defects: Guided tissue regeneration. *Periodontol* 2000 2000;22:104–132.
22. Seshima F, Bizenjima T, Aoki H, et al. Periodontal regenerative therapy using rhFGF-2 and deproteinized bovine bone mineral versus rhFGF-2 alone: 4-year extended follow-up of a randomized controlled trial. *Biomolecules*. 2022;12:1682.
23. Murakami T, Matsugami D, Yoshida W, et al. Healing of experimental periodontal defects following treatment with fibroblast growth factor-2 and deproteinized bovine bone mineral. *Biomolecules* 2021;11:805.
24. Shirakata Y, Setoguchi F, Sena K, et al. Comparison of periodontal wound healing/regeneration by recombinant human fibroblast growth factor-2 combined with β -tricalcium phosphate, carbonate apatite, or deproteinized bovine bone mineral in a canine one-wall intra-bony defect model. *J Clin Periodontol* 2022;49:599–608.
25. Di Tullio M, Femminella B, Pilloni A, et al. Treatment of supra-alveolar-type defects by a simplified papilla preservation technique for access flap surgery with or without enamel matrix proteins. *J Periodontol* 2013;84:1100–1110.
26. Jentsch H, Purschwitz R. A clinical study evaluating the treatment of supra-alveolar-type defects with access flap surgery with and without an enamel matrix protein derivative: A pilot study. *J Clin Periodontol* 2008;35:713–718.
27. Yilmaz S, Kuru B, Altuna-Kıraç E. Enamel matrix proteins in the treatment of periodontal sites with horizontal type of bone loss. *J Clin Periodontol* 2003;30:197–206.
28. Mourlaas J, Cortasse B, Vigouroux F, Dagba A. The tunnel wall approach and enamel matrix derivative to cover exposed roots and improve clinical attachment levels in Cairo class III defects associated with an intrabony lesion in the anterior area: Three cases. *Int J Periodontics Restorative Dent* 2023;43:95–102.
29. Ogawa Y, Maekawa S, Imamura K, Ishikawa T. Supra-alveolar periodontal tissue reconstruction in a case with severe periodontitis: Case report with a 2-year follow-up. *Int J Periodontics Restorative Dent* 2023;43:212–221.

Shota Tsuji, DDS, MS

Private practice, Osaka, Japan; Department of Periodontics and Regenerative Dentistry, Osaka University, Graduate School of Dentistry, Osaka, Japan.

Shu Hoshi, DDS, PhD

Private practice, Niigata, Japan; Department of Periodontology, Graduate School of Medical and Dental Sciences, Tokyo Medical and Dental University, Tokyo, Japan.

Shogo Maekawa, DDS, PhD

Department of Periodontology, Graduate School of Medical and Dental Sciences, Tokyo Medical and Dental University, Tokyo, Japan.

Correspondence to:

Dr Shota Tsuji, stsujiadds@gmail.com